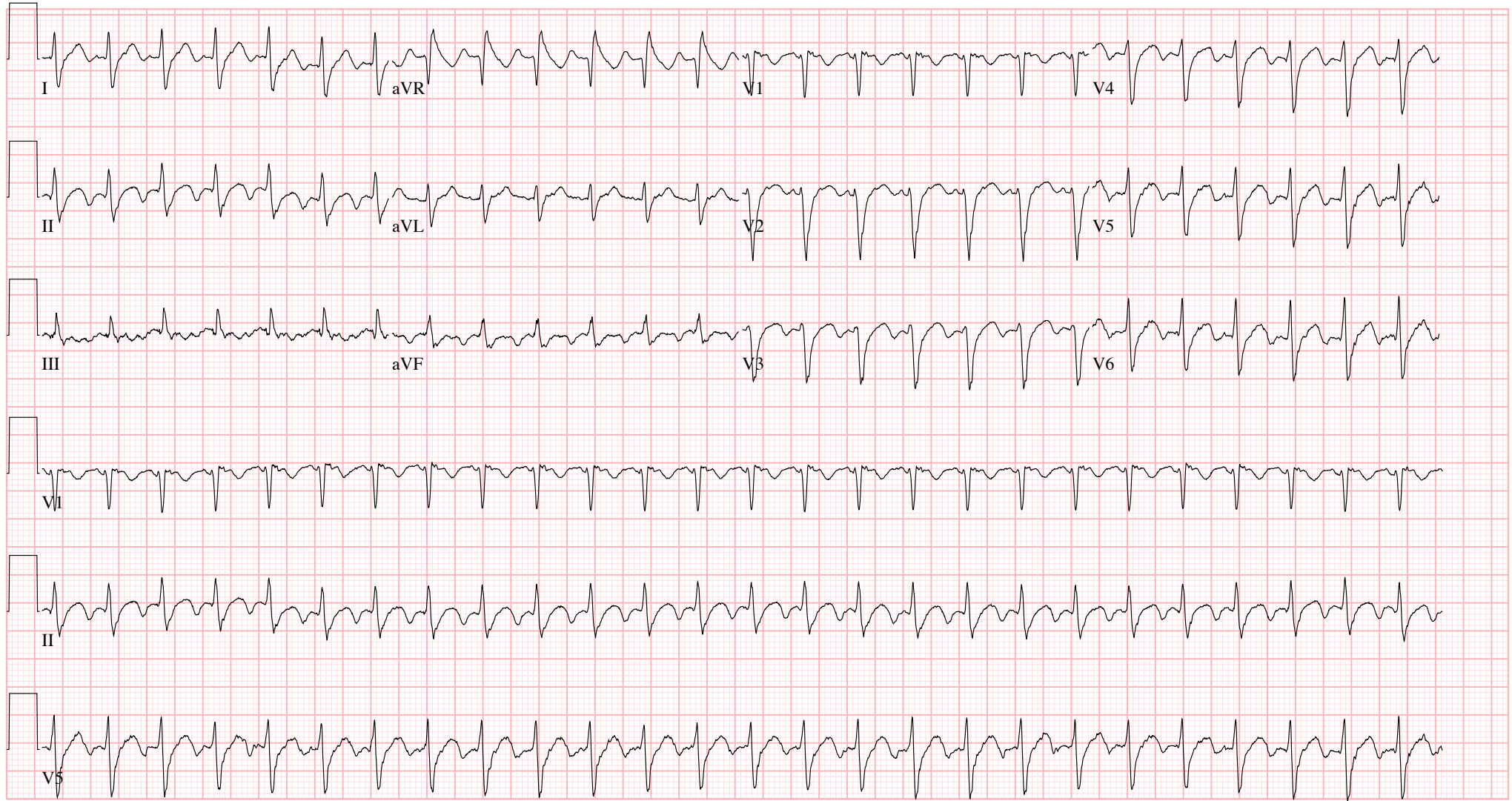




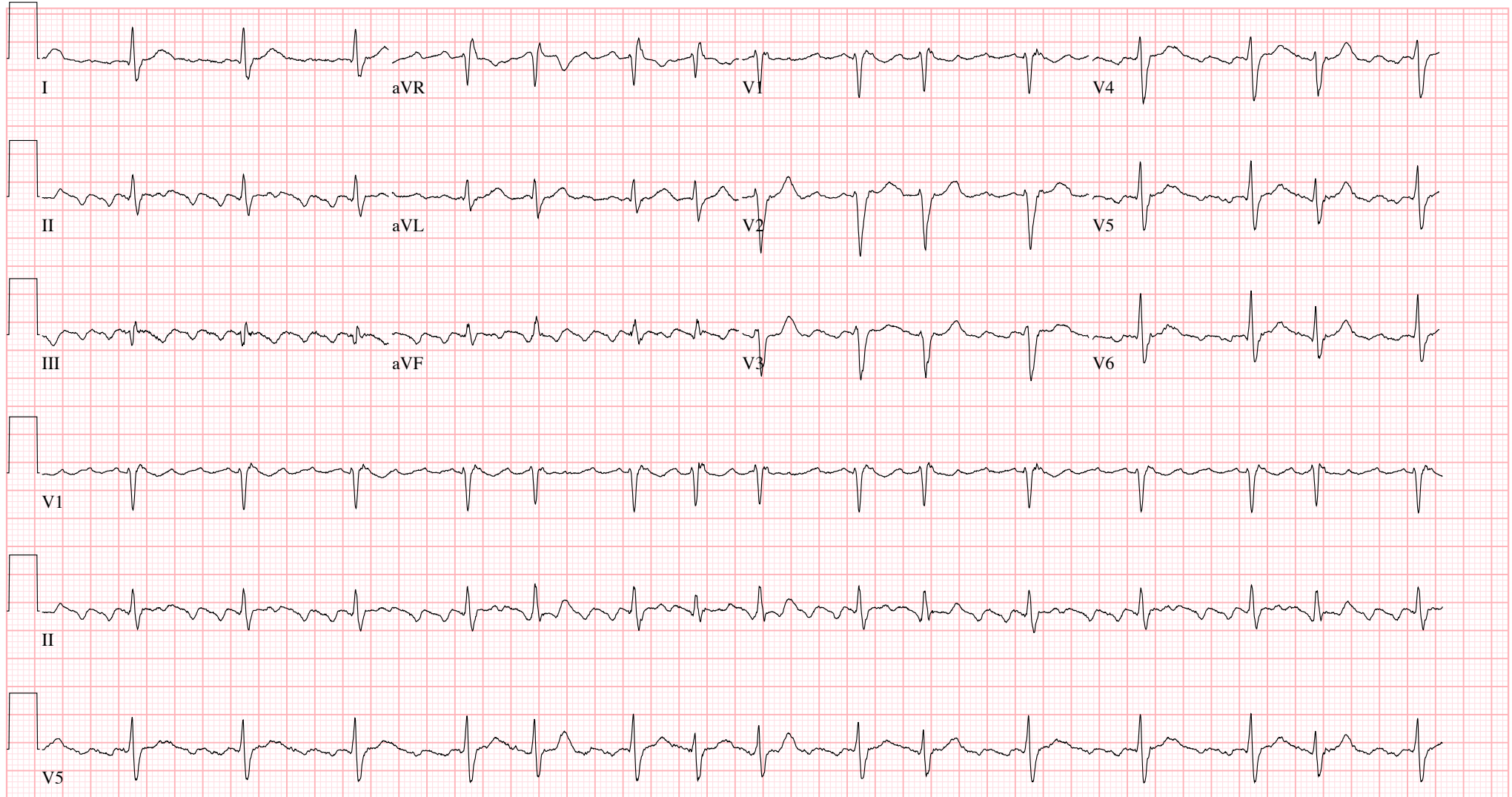
**A 40-year-old man presents with lightheadedness and palpitations.**



25mm/s 10mm/mV 150Hz



After administration of a medication this is what you see. What rhythm is this and what medication may have been given?



25mm/s 10mm/mV 150Hz